

PRP Matrix Grafts Current Knowledge and Application Techniques in Musculoskeletal Medicine

David M. Crane, MD
Peter A.M. Everts, PhD

Platelet Rich Plasma (PRP) grafting techniques are now being utilized in musculoskeletal medicine with increasing frequency and effectiveness. Soft tissue injuries treated with PRP include tendonopathy, tendonosis, acute and chronic muscle strain, muscle fibrosis, ligamentous sprains, and joint capsular laxity. PRP has also been utilized to treat intra-articular injuries. Examples include arthritis, arthrofibrosis, articular cartilage defects, meniscal injury and chronic synovitis or joint inflammation.

Platelet Rich Plasma is now being utilized by musculoskeletal (MSK) providers following the effective use in multiple specialties. Autologous PRP was first used in cardiac surgery by Ferrari et al. in 1987 as an autologous transfusion component after an open heart operation to avoid homologous blood product transfusion (1). PRP has also been used in multiple specialties such as maxillofacial, cosmetic, spine, orthopedic, podiatric and for general wound healing (2, 3).

MSK providers began using PRP for tendonosis and tendonitis in the early 1990s (4). PRP techniques have most commonly been applied by MSK providers previously trained in the use of and on the knowledge backbone of prolotherapy. Although a paucity of well designed, randomized trials exists for its use in MSK medicine, animal studies, case reports, and anecdotal evidence suggests that this technique will continue to develop as a way to regenerate tissue that has lost its inherent homeostasis thereby relieving pain and dysfunction.

A Word about Words – Standardizing the Nomenclature for PRP

The authors define a PRP Matrix Graft as: A tissue graft incorporating autologous growth factors and / or autologous undifferentiated cells in a cellular matrix whose design depends on the receptor site and tissue of regeneration.

In reading the literature, different verbiage will arise, such as platelet leukocyte gel, platelet rich plasma gel, platelet concentrate, blood plasma therapy... When examining the literature, evaluate if concentrations of platelets, nucleated cells, growth factors, and fibrin are measured and if platelet activation is measured. These factors all contribute to the effectiveness of therapy, along with skillful percutaneous injection and surgical techniques (5). Everts, on review of 28 human studies, found 7 that showed either no benefit or negative effects of PRP (3). When these studies were reviewed, many had very small sample sizes (as few as 3 patients) and several had platelet portions that had been activated prior to use via differing means. Hopefully in the near future the nomenclature will benefit from some form of standardization. It is the author's experience, however, that the wording of 'graft' is required in the name for third party reimbursement reasons. This is also how this modality is utilized at present in the office and surgical settings and therefore the use of the word graft is justified.

PRP Matrix Grafts – Constituents and properties of an effective regenerative graft

Normal tissue homeostasis is maintained in a prescribed physiologic manner. These stages will be reviewed from a hypothetical time of injury through the healing phase to understand how to maximize graft preparation.

Platelets contain two unique types of granules. **Alpha-granules** contain a variety of hemostatic proteins (coagulation proteins), as well as growth factors, cytokines, chemokines (pro-inflammatory activation-inducible cytokines) and other proteins such as adhesion proteins (6). Of primary interest to the clinician are the three adhesion molecules and 7 growth factors present in the alpha granule (7). **Dense granules** contain factors that promote platelet aggregation (ADP, calcium, serotonin). Cell activation of platelets causes the discharge of granule contents. Platelets, then, require activation in order to begin their cascade of events that lead to collagen restoration and growth. This activation must occur at the tissue level (where the platelets aggregate and adhere to collagen at the site of grafting) (5).

Table 1 Synopsis of growth factors present in PRP. From Peter A.M. Everts et al. Platelet-Rich Plasma and Platelet Gel: A Review (3).

Growth Factor	Source	Function
Transforming Growth Factor-beta, TGF-β	Platelets, extracellular matrix of bone, cartilage matrix, activated TH ₁ cells and natural killer cells, macrophages/monocytes and neutrophils	Stimulates undifferentiated mesenchymal cell proliferation; regulates endothelial, fibroblastic and osteoblastic mitogenesis; regulates collagen synthesis and collagenase secretion; regulates mitogenic effects of other growth factors; stimulates endothelial chemotaxis and angiogenesis; inhibits macrophage and lymphocyte proliferation
Basic Fibroblast Growth Factor, bFGF	Platelets, macrophages, mesenchymal cells, chondrocytes, osteoblasts	Promotes growth and differentiation of chondrocytes and osteoblasts; mitogenetic for mesenchymal cells, chondrocytes and osteoblasts
Platelet Derived Growth Factor, PDGFa-b	Platelets, osteoblasts, endothelial cells, macrophages, monocytes, smooth muscle cells	Mitogenetic for mesenchymal cells and osteoblasts; stimulates chemotaxis and mitogenesis in fibroblast/glial/smooth muscle cells; regulates collagenase secretion and collagen synthesis; stimulates macrophage and neutrophil chemotaxis
Epidermal Growth Factor, EGF	Platelets, macrophages, monocytes	Stimulates endothelial chemotaxis/angiogenesis; regulates collagenase secretion; stimulates epithelial/mesenchymal mitogenesis
Vascular Endothelial Growth Factor, VEGF	Platelets, endothelial cells	Increases angiogenesis and vessel permeability, stimulates mitogenesis for endothelial cells
Connective Tissue Growth Factor, CTGF	Platelets through endocytosis from extracellular environment in bone marrow	Promotes angiogenesis, cartilage regeneration, fibrosis and platelet adhesion

A PRP Matrix Graft is made in an office or operative setting by using one of the several available table-top machines on the market. Several authors offer reviews of available graft preparation centrifuges and their ability to concentrate growth factors (2,3,8). Each machine has a separate, disposable unit that concentrates platelets in a small amount of plasma. A thin layer of platelets is found immediately above the leukocytes in the buffy coat of centrifuged blood. When a concentrated platelet portion is made, the buffy coat containing elevated levels of leukocytes along with concentrated platelets are suspended in a small amount of plasma for subsequent grafting. The clinician hopes that the platelets are not activated and remain suspended until grafting and contact with thrombin or collagen occurs.

For our purposes, we will consider **PRP gel** as PRP that is activated with either autologous thrombin and calcium, bovine thrombin and calcium, or thrombin alone. Autologous PRP gel stipulates the use of autologous thrombin. The authors consider a PRP Matrix Graft to include gel or no gel. This must be stipulated at the time of treatment. Again, the tissue of treatment will demand what matrix, if any, is added or utilized.

Normal platelet activation leads to three necessary stages of healing: Inflammation, Proliferation, and Remodeling (9). If any of these stages are incomplete, or if they proceed unabated, tissue homeostasis is lost and pain and loss of function may result. Most reviews on this topic focus on only the

growth factors contained within the alpha granule of the platelet which is released upon platelet activation. It is important to understand, however, that if the platelets aren't suspended with biologic levels of other constituents of plasma such as leukocytes, cytokines, and fibrin (the Matrix), the graft is either not effective or less effective (3). If fibrin levels are too high, or platelet activation occurs prior to collagen binding, the graft is also inhibited. Other functions of platelet activation and the subsequent cascade of events that occur include cytokine signaling, chemokine release, and mitogenesis (9).

- Inflammatory phase - Functions of platelets upon activation
 - Anti-microbial
 - Adhesion
 - Aggregation
 - Clot retraction
 - Pro-coagulation
 - Cytokine signaling
 - Chemokine release
 - Growth factor release

There is now evidence to suggest that at certain concentrations, or dose response curves, platelet rich plasma grafts may be anti-inflammatory or pro-inflammatory in certain tissues (10). A dose response relationship exists to some unknown level of concentration with migration and proliferation of progenitor stem cells to tissue upon grafting of PRP concentrate at the tissue injury site (11).

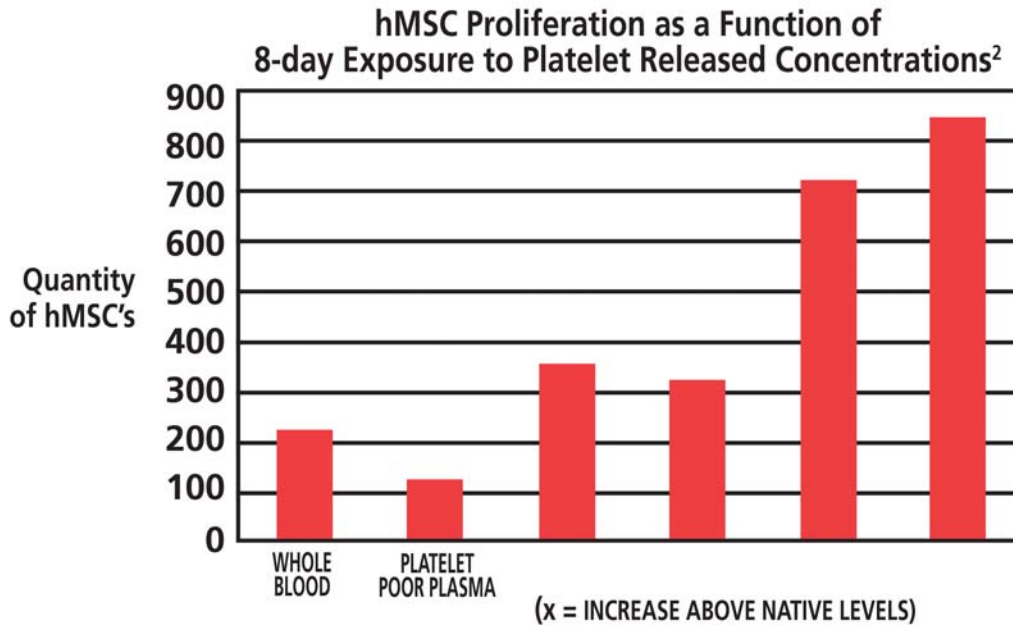


Fig. 1 shows the relationship of differing platelet concentrations and human mesenchymal stem cell (hMSC) migration and proliferation. From: Haynesworth, Stephen et al. Mitogenic Stimulation of Human Mesenchymal Stem Cells by Platelet Releaseate. Poster Presentation, American Academy of Orthopedic Surgery, March 2001.

There is emerging evidence to suggest that PRP grafts in the 4 – 6 fold range (10^6 platelets) have more anti-inflammatory mediators and effects and are clinically relevant and useful for most situations. PRP grafts in the 8 – 13 may be pro-inflammatory in nature (10). Further elucidation of this effect is required, however, as some studies showed beneficial effects of higher concentrations of PRP (12).

Hesham El-Sharkawy et. al evaluated this effect in periodontal tissue. The conclusions were that PRP is a rich source of growth factors and promoted significant changes in monocyte-mediated proinflammatory cytokine/chemokine release. LXA4 was increased in PRP, suggesting that PRP may suppress cytokine release, limit inflammation, and, thereby, promote tissue regeneration (10).

Weibrich et al. observed an advantageous effect with platelet concentrations of approximately $10^6/\mu\text{L}$. Furthermore, they state that higher concentrations might have a paradoxically inhibitory effect (13).

Following the initial inflammatory phase, which typically lasts for two to three days, fibroblasts enter the site and begin the proliferative phase (9). Low pH and low oxygen levels stimulate fibroblast proliferation in the injury site (14). Fibroblasts become the most abundant cell by day no. 7. The fibroblasts are then responsible for deposition of collagen and ground substance. This phase lasts for two to four weeks. As these are primarily our deficient cells with chronic injury (lack of normal collagen in extracellular matrix), this stage is mandatory for MSK repair.

The Proliferative Phase – Fibroblast function

- Wound contraction
- Peaks day 5-15
- Can last for weeks
- Fibroblasts differentiate into myofibroblasts
- Actin contracts making wound smaller

Low pH and hypoxemia also stimulates neovascularization. Neovessels begin to form at approximately day 5 to 7 and this process proceeds until the neovessels disappear near completion of the remodeling phase.

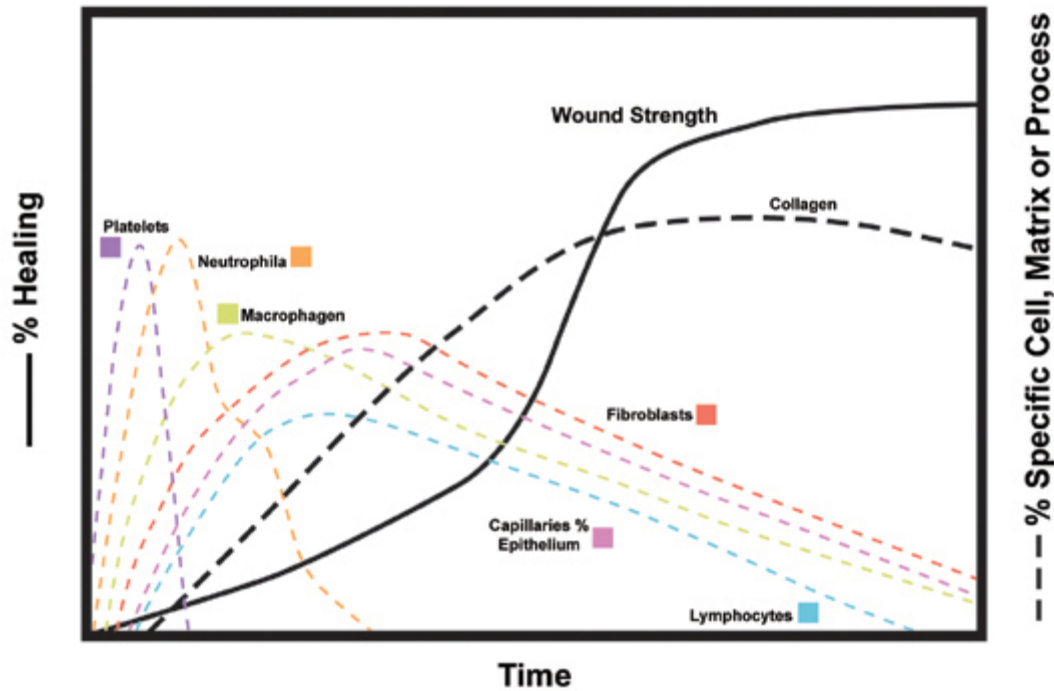


Fig. 2 the cellular components involved in the three phases of inflammation (15).

The Remodeling Phase – Collagen maturation and strength. Biotensegrity repair

- Starts when production and break down of collagen equalize
- Can last over a year
- Type III collagen is replaced by Type I collagen
- Reorganization occurs
- Blood vessels disappear (9)

It has become apparent, then, that PRP Grafts function via a triad of interactions, known as the cell proliferation triangle (16, 17). Each piece of this triangle must be present for effective tissue repair and pain relief.

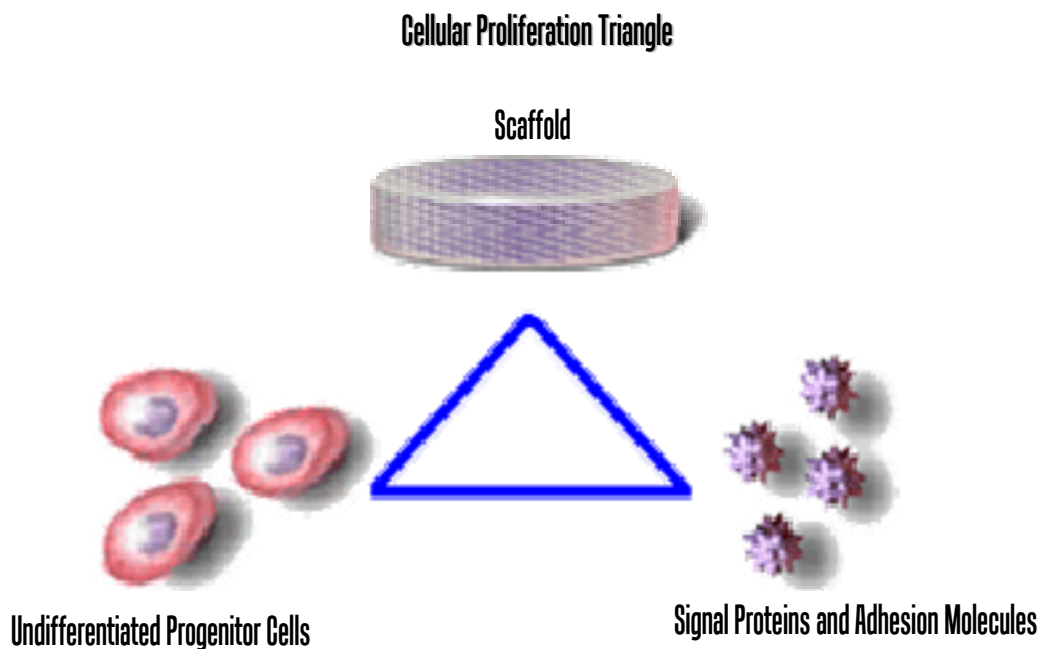


Fig. 3 shows the three components required in a graft to stimulate adequate healing in degenerative tissue

When making a graft for clinical use the constituents of each of these three must be considered. i.e. is there an inherent matrix to place the graft in, or will the graft be washed away with motion, synovial fluid, or repeated graft compression or distraction. Does the patient have an adequate response for inflammation and are there adequate numbers of platelets to concentrate for progenitor cell mitogenesis and proliferation.

Biotensegrity – A construct for regeneration of tissue

Biotensegrity refers to a dynamic construct of compressive and tensional forces acting on and through multiple levels of organization to maintain or repair tissue homeostasis. Biotensegrity, then, is a repeated pattern of structural and functional architecture of all living tissue (19, 20).

The probable link though all levels of biotensegrity is the vascular endothelial system with its regenerative and neuroendocrine functions as subsequently described.

Endothelial cells line the lumen of all blood vessels as a single squamous epithelial cell layer. They are derived from angioblasts and hemangioblasts.

Weibel-Palade bodies are specialized secretory granules found in endothelial cells. These vesicles store preformed hormones, cytokines, and growth factors, as well as enzymes, receptors, and adhesion molecules, which can be released and/or expressed on the cell surface without de novo protein syntheses by regulated exocytosis in response to stimulation of cell activation (6).

Thus, the authors believe there is sufficient evidence to suggest that the vascular endothelial system links all of the biotensegrity levels together as the various factors are at work up and down the scale.

Contraindications to the use of PRP Matrix Grafts (3,21,22):

- Contraindications (Absolute)
 - Platelet dysfunction syndrome
 - Critical thrombocytopenia
 - Hypofibrinogenemia
 - Hemodynamic instability
 - Septicemia
 - Sensitivity to bovine thrombin
 - If using bovine thrombin with calcium to make platelet gel

- Contraindications (Relative)
 - Consistent use (anti-inflammatory use) of NSAID's within 48 hours of procedure
 - Corticosteroid injection at treatment site or systemic use of corticosteroids within 2 weeks of graft procedure
 - Recent fever or illness
 - Rash at graft donor site or at receptor site
 - Cancer – especially hematopoietic or of bone
 - Active history or history of *Pseudomonas*, *Enterococcus* or *Klebsiella* infection, as PRP has been shown in one study to potentially stimulate these pathogens (22).
 - HGB <10 g/dl
 - platelet count less than $10^5/\mu\text{L}$

Risks involved with the use of PRP Matrix Grafts:

Few randomized, placebo controlled trials exist regarding the utilization of these grafts. There have been no reports of worsened pain or function following tissue maturation that the authors could find, however. In the author's experience of performing approx. 20 – 30 cases of percutaneous PRP Matrix Grafts per week for the last three years, no patients reported worsened pain or function. It is felt by the authors and expressed in the available literature, then, that this procedure technique is safe and effective.

Pain at the treatment site is common for a short period following injection. One of the author's (DC) patients reported worsened pain for six months at a treated lateral epicondyle. This subsequently resolved and has been absent for over one year. This stresses the fact that remodeling of the tissue is necessary to see the effects of therapy.

No tendon rupture or partial rupture was noted. Olena Virchenko and Per Aspenberg noted in a rat Achilles tendon transection model that 1 postoperative injection resulted in increased strength after 4 weeks. This effect was obliterated with the use of botox at the site (18). No reports of tendon or ligament rupture exist following PRP that the authors can find.

Other risks that occur at time of injection include injury with pain induced syncope. Indeed, the main complaint received from patients is the pain of injection of the PRP. A risk of limb injury following the graft procedure exists, as local or regional anesthesia is used at the time of procedure. One of the authors (DC) had a patient who stepped from a ladder approx. 4 hours following an Achilles and peroneal tendon injection, with subsequent inversion and fracture of the ankle. This may have been the result of proprioceptive and sensory loss with anesthesia.

Percutaneous Needle Techniques

The risk of puncturing a hollow organ must be explained. This risk is not expected to be above or below that of other needle techniques employed in clinical medicine.

Infection

The use of autologous blood products such as PRP to treat injury and disease reduces the risk of transmissible infection and allergic reaction.

The accepted risk of introduction of infection with percutaneous techniques has been reported as 1:50,000 injections. Since PRP is an autologous preparation the risk of introducing foreign material is effectively eliminated, although the entire procedure must be carried out in sterile conditions. PRP use with its initial inflammatory phase is also bacteriocidal, particularly against *Staphylococcus aureus* and *Escherichia coli* as shown by Bielecki et al. PRP gel seemed to induce the *in vitro* growth of *Ps. aeruginosa*, suggesting that it may cause an exacerbation of infections with this organism. There was no activity against *Klebsiella pneumoniae* or *Enterococcus faecalis*. The temporary formation of platelet and fibrin plugs at the wound site has also been noted to prevent the entry of microorganisms (3,22).

Other considerations come into play if the procedure is not performed with completely autologous preparations. PRP gel techniques that rely upon the use of bovine thrombin, which may contain contaminants like bovine Factor Va as a platelet activation source, may result in antibodies to Factors V and VI, with potentially life threatening coagulopathies resulting (5). Other concerns with bovine thrombin include prion disease, although none are reported in the literature. The authors have neither seen nor heard of any infections occurring with the percutaneous use of PRP or biocellular therapeutic grafts.

Carcinogenesis

Growth Factors act on cell surface receptors, do not enter the cell, and do not cause DNA mutation. There is no plausible mechanism by which growth factors result in neoplastic development, and there have been no reports of this in the literature (3,21). Furthermore, Scott and Pawson showed that growth factors (PGF) activate normal rather than abnormal gene expression (23).

Typical Treatment regimen with PRP

- **Consent**
 - Average series of injections is two to three at 4 – 6 week intervals
 - Different sites or areas of treatment may expand or contract with further treatment
 - You must functionally retrain the kinetic chain once the tissue has undergone some degree of healing

- **Risks:**
 - 1 : 50,000 chance of introducing infection with injection procedure
 - Allergy to local anesthetic(s)
 - Syncope with pain / blood at the time of injection
 - Injury occurrence with numbness or pain following procedure. i.e. falling, ankle sprain with inversion, etc.
 - Though extremely rare, pain or function may worsen
 - Puncture of tissue outside of intended graft site. i.e. vascular, neural, lung, or other tissue placements

- **Technique for myotendinous or teno-osseous sites**
 - Alcohol or Betadyne prep
 - We prefer betadyne gel when using an ultrasound probe for ‘live’ injection guidance
 - +/- Ethyl Chloride spray
 - Inject PRP with approximately 1cc PRP per cm³ of tissue / interface
 - Important to touch bone and ‘pepper’ the area of teno-osseous junction to stimulate the greatest number of fibroblast colonies
 - For myotendinous sites use U/S to ensure layered treatment throughout the tendon
 - Sterile band-aid applied post injection
 - Kinesiotape to protect motion if needed

- **Technique for intra-osseous sites**
 - Alcohol or Betadyne prep
 - We prefer betadyne gel when using an ultrasound probe for ‘live’ injection guidance
 - +/- Ethyl Chloride spray

- Local anesthetic either mixed with the PRP graft or to sites of tenderness to ‘road test’ the area prior to using the graft. This ensures that the PRP matrix graft is placed in the proper areas.
- Aspirate degenerative joint fluid prior to PRP matrix graft placement
- Gel the PRP or utilize other stabilizing matrix for intra-articular sites. Ligaments, tendons, and inherent matrix sites do not require gel in the author’s experience
- 8 – 10cc PRP matrix graft is the typical amount used for a knee or shoulder joint in our clinic
- “Treat regionally, not locally” -D. Crane MD
 - Treat all of the capsule that is tender along with tendinous and ligamentous sites of tenderness in addition to the intra-articular capsule

It should be noted that Kevy and Jacobson have evaluated the mixture of common local anesthetics with PRP and find no significant platelet activation or diminution of graft growth factor functions (7, personal communication February 2007, Center for Blood Research, Cambridge, Massachusetts).

Tendonosis and the use of PRP

In vitro studies of collagen and tendon:

Anitua in 2005 showed that autologous preparations rich in growth factors promote proliferation and induce VEGF and HGF production by human tendon cells in culture (24). Mishra performed an in vitro study which determined the effect of a platelet concentrate medium on the proliferation of human skin fibroblasts, which are the cells responsible for deposition of collagen. Buffered PRP augmented human fibroblast proliferation when compared to control (25).

Schnabel evaluated gene expression patterns, DNA, and collagen content of equine flexor digitorum tendons cultured in media consisting of PRP and other blood products. PRP at 100% concentration stimulated the greatest number of collagen type I, collagen type III and cartilage oligomeric protein (COMP) molecule genes without increasing expression of the pro-inflammatory matrix metalloproteinases. ELISA detected higher levels PDGF & TGF-B in the PRP group (26).

Hesham El-Sharkawy et al. measured platelet derived growth factor (PDGF)-AB, PDGF-BB, transforming growth factor-b1, insulin-like growth factor-I, fibroblast growth factor-basic (FGF-b), epidermal growth factor (EGF), vascular endothelial growth factor, interleukin-12 (p40/70), and regulated on activation, normal T-cell expressed and secreted (RANTES) levels by enzyme-linked immunosorbent assay. Cytokine, chemokine, and LXA4 levels as well as monocyte chemotactic migration were analyzed. PRP led to significantly increased levels of growth factors and significantly suppressed inflammation by promoting secretion of LXA4. These growth factors stimulated the proliferation of fibroblasts and periodontal ligament cells, as well as extracellular matrix formation, and promoted collagen and total protein synthesis while stimulating the synthesis of hyaluronate from gingival fibroblasts. IGF-I levels in PRP in this study were not significantly different from PPP, suggesting that other cell types could be responsible for the release of this growth factor (10).

Tissue culture studies performed by du Toit et al. for use in dermal regeneration confirmed the potent mitogenic stimulation of human fibroblasts, keratinocytes, chondrocytes, neural tissue and myoblasts (27).

In vivo human studies:

Tendon and Ligament use of PRP: A review and case example

Mishra evaluated 20 patients that failed non-operative treatment for chronic epicondylar pain. These 20 patients were randomized to a single PRP injection or injection with bupivacaine. Mishra comments that the IRB would not allow a blood draw from the control patients to blind the study. All PRP patients had lower pain and greater ROM than control (bupivacaine). Eight weeks after the treatment, the platelet-rich plasma patients noted 60% improvement in their visual analog pain scores versus 16% improvement in control patients. Sixty percent (3 of 5) of the control subjects withdrew or sought other treatments after the 8-week period, preventing further direct analysis. Therefore, only the patients treated with platelet-rich plasma were available for continued evaluation. At 6 months, the patients treated with platelet-rich plasma noted 81% improvement in their visual analog pain scores ($P = .0001$). At final follow-up (mean, 25.6 months; range, 12-38

months), the platelet-rich plasma patients reported 93% reduction in pain compared with before the treatment ($P < .0001$). Of importance, no PRP-treated patient was worse after treatment, and there were no complications in this study (28).

Barrett et al demonstrated in a series of 9 plantar fascia patients that PRP, with ultrasound guidance, could be safely injected into the medial and central bands of the most affected plantar fascia with promising results. Seven out of nine patients had complete resolution of their plantar fascial pain at 1 year and all the patients in the study had improvement that was noted on diagnostic ultrasound. One of the patients was considered a failure because of a subsequent steroid injection even though all pain had resolved (29).

Scarpone reports on a prospective study carried out in 14 patients with shoulder pain. The patients all had rotator cuff tears with no significant AC joint thickness with impingement and no other significant symptomatic pathology including labral tears, glenohumeral arthrosis, or gross instability. All of the patients failed non-operative treatments such as NSAIDs, physical therapy, and corticosteroid injections and all patients were considering surgical options. Of the 14 patients, 12 had statistically significant improvements in their pain scale and their strength and endurance at 8 weeks. Of the 12 patients, 6 had radiographic evidence of healing of their tendinopathy on MRI at 8 weeks. Of the 4 patients who were considering surgery because of persistent pain, only 2 went on to have rotator cuff surgery. No significant complications were noted (30).

Ventura et al. evaluated PRP in ACL repair. A total of 20 patients with anterior cruciate ligament (ACL) injuries were treated by quadrupled hamstring tendon graft (QHTG) with or without PRP gel growth factor (GF) application. CT highlighted a significant difference ($p < 0.01$) between ACL density of the two groups. CT densities of the ACL and posterior cruciate ligament (PCL) were similar in GF-treated group. In the control group, however, the intensity of the signal was heterogeneous and the new ACL was not clearly identifiable with respect to the PCL. A different density of the ACL was also noted: in the GF-treated group this density was uniform and the new ACL was more structured, while in the control group the ligament was less structured and did not completely fill the femoral and tibial tunnels. In the PRP treated group one patient had a synovitic reaction.

On CT, the new ACL was increased and hypertrophic and surrounded by a soft-tissue reaction. MRI confirmed this finding (31).

Sanchez reports on a Case-Control Study of 12 athletes with complete achilles rupture. All 12 had open achilles repair. 6 had PRGF. The treatment group had no wound complications, earlier ROM (7 vs. 11 wks), jogging (11 vs. 18 wks), and training (14 vs. 21 wks). The authors of this study measured IGF-1, TGF-B1, PDGF-AB, EDF, VEGF, & HGF and noted that the number of platelets held direct correlation to level of growth factors (32).

Case Example: Chronic tendonopathy

63yo male ironman distance triathlete with h/o left achilles pain >3months. The patient had no relief with physical therapy or U/S therapy for a 6 week duration. The patient was diagnosed by MRI with stress fracture of the fibula with no discrete cortical line or fracture in addition to an achilles tendonopathy. Diagnostic U/S in our office shows an 8cm segment of tendon collagen change consistent with a tendonopathy with associated peritenon fibrosis.

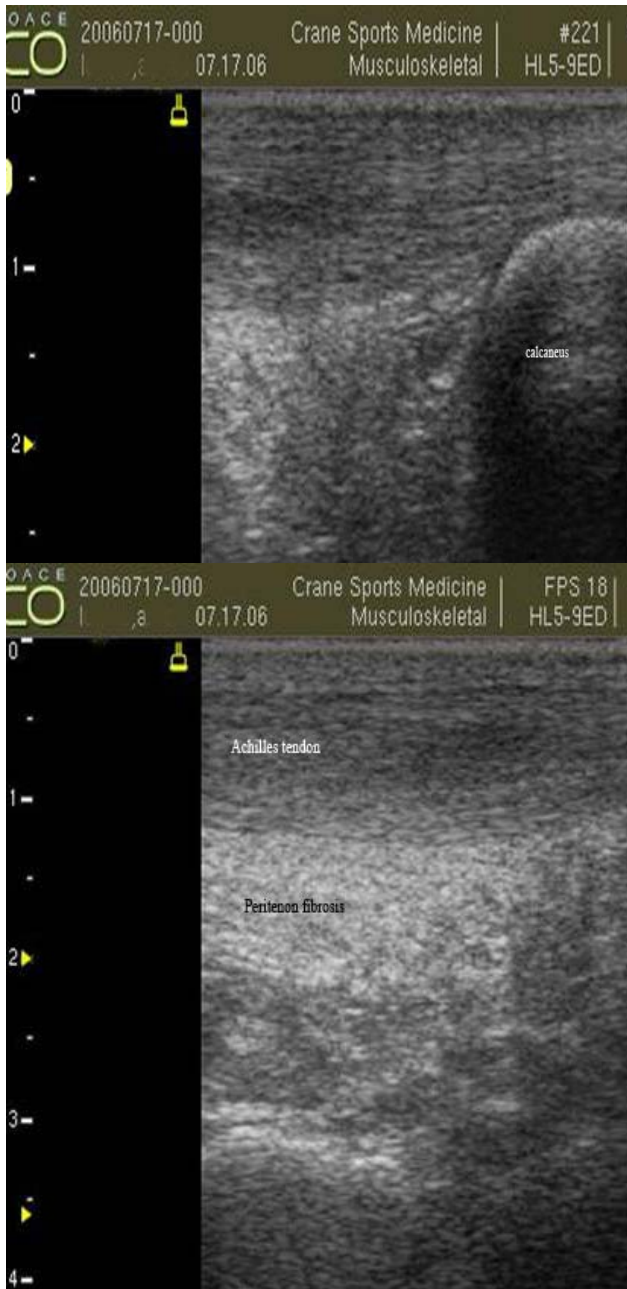

Fig. 4 Diagnostic ultrasound of the left achilles (proximal and distal) showing a large hypoechoic noninsertional tendonosis with surrounding fibrosis

The patient undergoes three separate series of PRP at 4 week intervals to the Achilles tendon and fibula along with the peroneal tendon sheath at the myotendinous junction. Subsequent ultrasounds show improved fibrosis and less scarring along with collagen pattern reorganization consistent with improved vascularity and tendon structure.

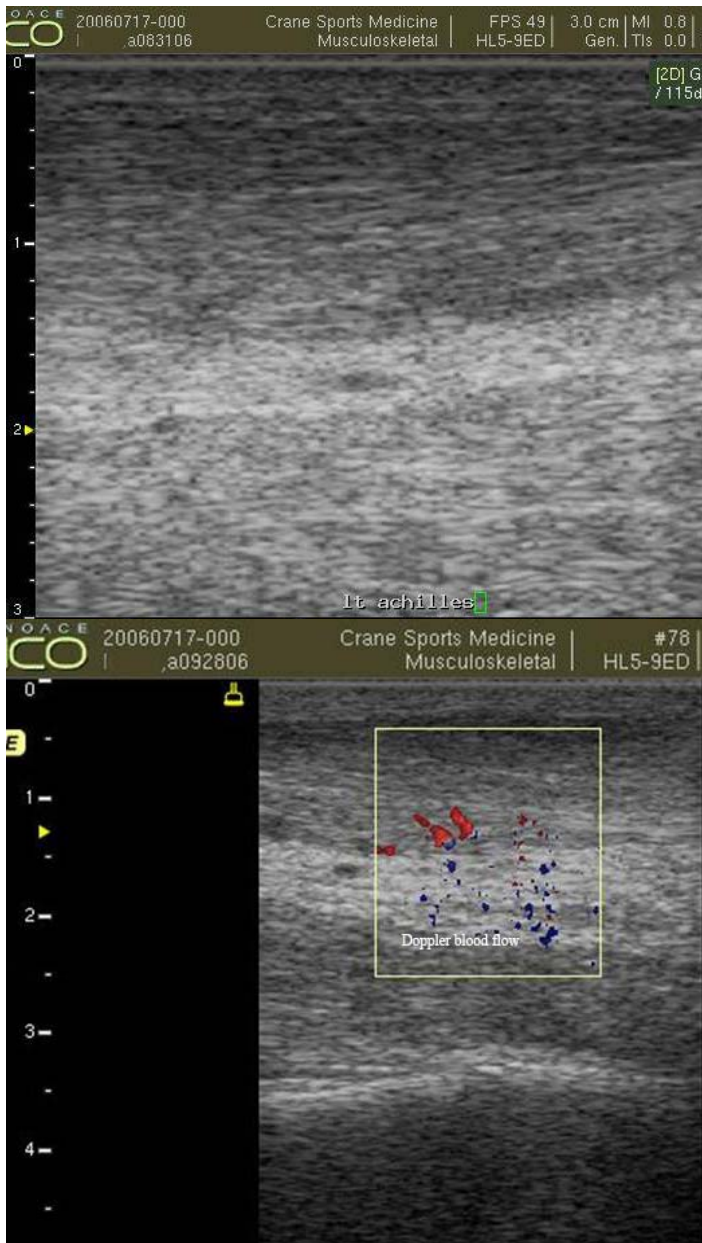


Fig. 5 Diagnostic ultrasound of the left Achilles taken 1.5 months after initial PRP matrix grafting showing improved collagen organization, lessened fibrosis, and improved capillary blood flow

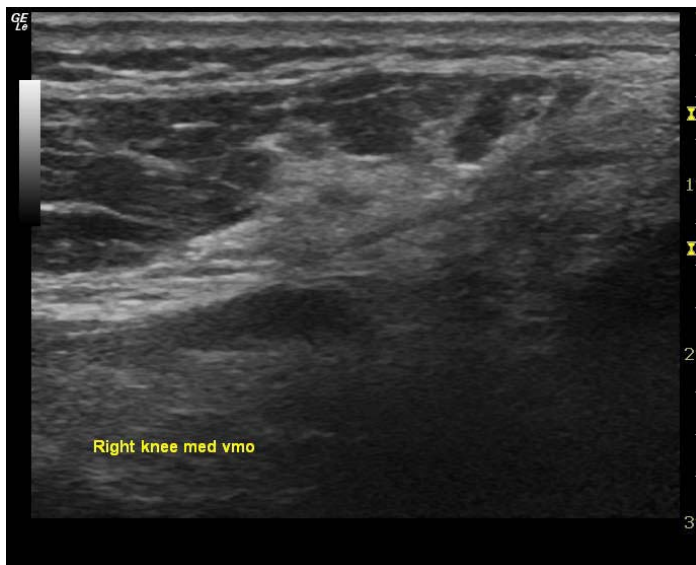The patient has > 90% pain reduction after three PRP matrix grafts and returns to ironman distance racing after the three months of restricted training. Supportive compression sleeves are utilized for three months to allow for load distribution until strength in the peroneal muscles and achilles is 90% of the unaffected right side.

Muscle Strain and the use of PRP: A review and case example

Sanchez reports a 20 patient prospective muscle injury pilot study with 6 month follow-up. Ultrasound guided injection of PRP within the injured muscle enhanced healing (echo-graphic images) and functional capacities 50% faster than the control group (33).

Case Example: Quadriceps VMO muscle strain

56yo male with right thigh pain for approximately one year. The pain is worse on the bike, and in fact is more prevalent when seated and pushing large gears or uphill climbing. The patient has no significant pain with running. The patient is an ironman distance triathlete and remembers no injury of significance 1 year ago at onset. Ultrasound shows a vastus medialis injury / strain pattern with associated fiber tearing and fibrosis. This is near the VMO myotendinous junction at the right knee. No evidence of knee pathology is noted on physical exam or on ultrasound. Palpable tenderness exists at the strain site on the medial thigh. Pain is also reproduced on eccentric loading of the VMO muscle group. No improvement had been obtained previously with 3 weeks of NSAID use or with physical therapy or myofascial therapy work.



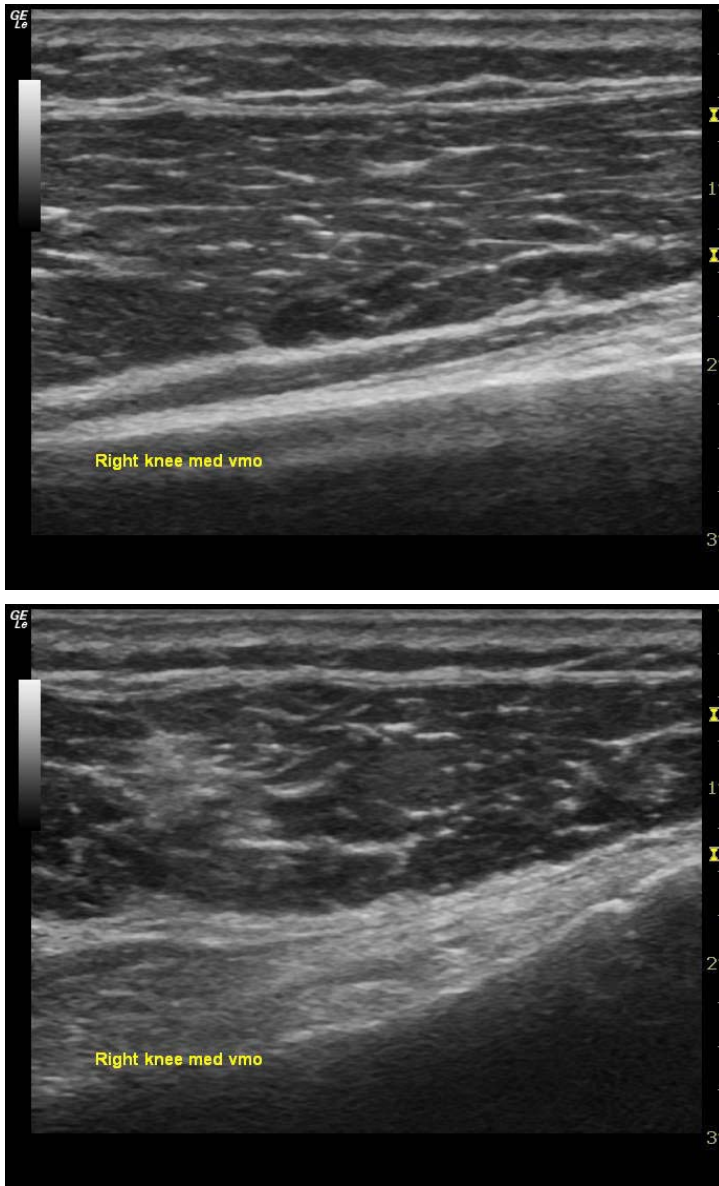


Fig. 6 U/S pictures (3) proximal and distal chronic tendonopathy with scarring and fibrosis of the VMO at the myotendinous junction and insertion

The patient undergoes a single injection of PRP (4cc) along with 1cc of injectable collagen for matrix stabilization at two discrete sites in the VMO muscle with ultrasound guidance.

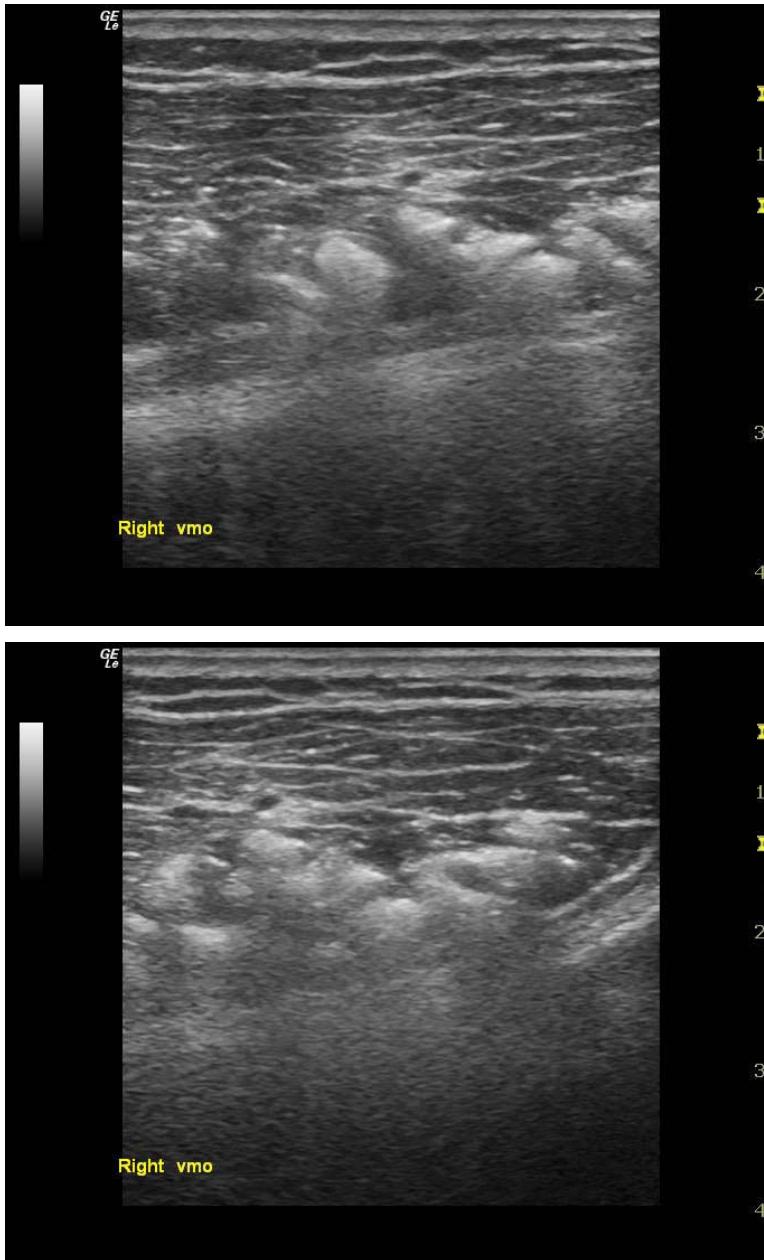


Fig. 7 U/S pictures (2) post injection with PRP and gel matrix at the myotendinous junction and the insertion.

The patients pain after 1 month is >80% resolved and the patient has no pain on the bike or with activity as previously noted. Resumption of training occurred 1 week following injection with swimming, running, and protected cycling.

Articular cartilage and the intra-articular use of PRP: A review and case example

Everts and Devilee et al. report that autologous platelet gel and fibrin sealant enhance the efficacy of total knee arthroplasty by improved range of motion, decreased length of stay and a reduced incidence of arthrofibrosis. Everts group also investigated whether the use of autologous derived platelet gel and fibrin sealant would reduce postoperative blood loss, decrease the impaired range of motion and the incidence of arthrofibrosis. Study group patients (n = 85) were treated with the application of autologous platelet gel and fibrin sealant at the end of surgery. Eighty patients were operated without the use of platelet gel and fibrin sealant, and served as the control group. During a 5-month postoperative period patients were followed to observe the incidence of arthrofibrosis. In patients in the treatment group the hemoglobin concentration in blood decreased significantly less when compared to the control group. They also showed a superior postoperative range of motion when compared to those of the control group ($P < 0.001$). The incidence of arthrofibrosis and subsequent forced manipulation was significantly less ($P < 0.001$) in patients managed with platelet gel and fibrin sealant (34).

Case Example: Severe Hip Osteoarthritis with a history of congenital hip dysplasia.

56yo female with increasing left hip pain for >1 year. The patient has a history of bilateral hip dislocations at birth (birth country Poland – no x-rays available) with evidence of shallow acetabular deformity noted on x-ray.

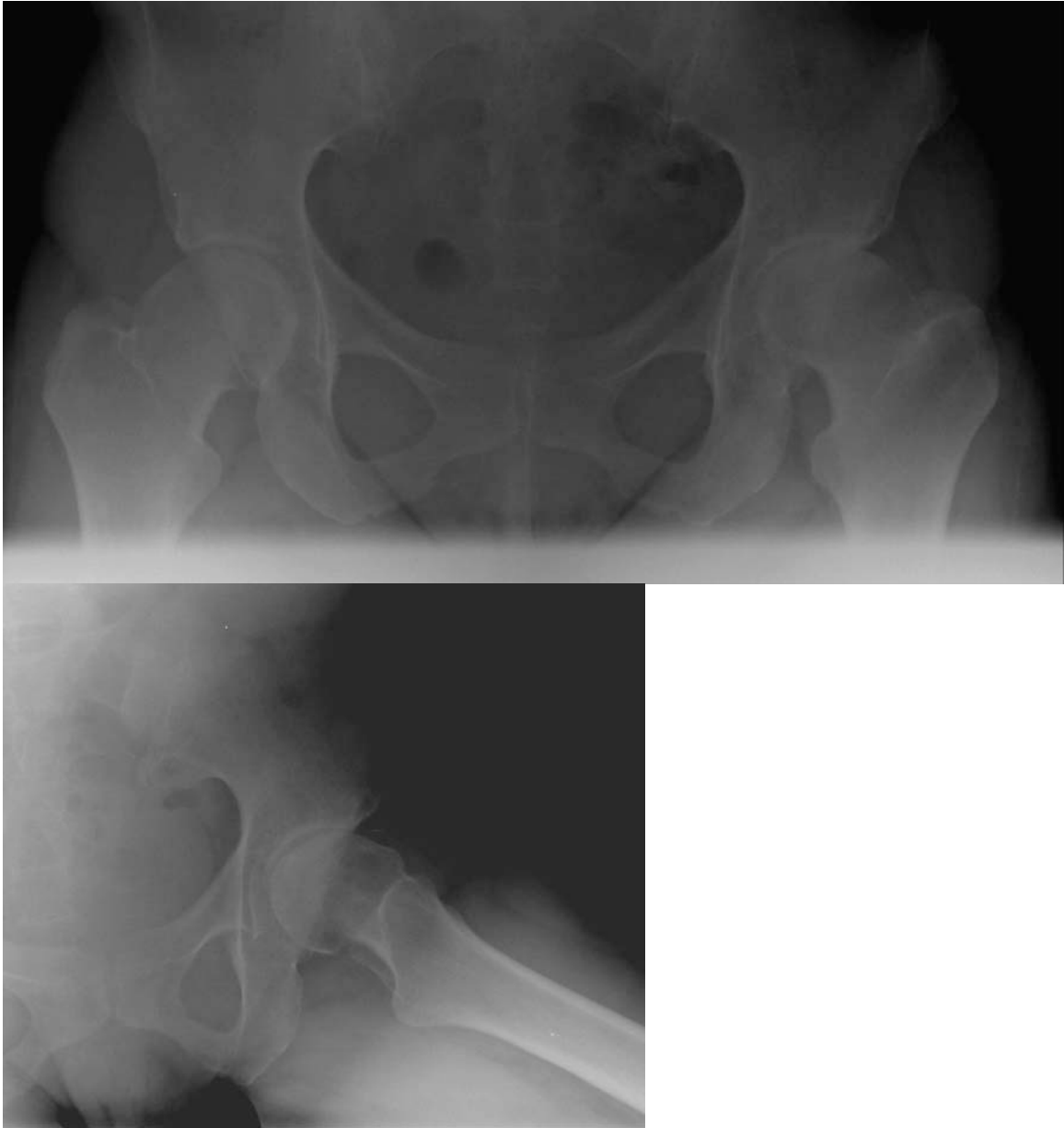


Fig. 8 X-ray pelvis and affected left hip pre-treatment with PRP matrix graft

The patient is active in dance and is of normal weight and BMI. Some relief is obtained with NSAID therapy but pain is now affecting sleep and is interfering with ADL's and her dance regimen. The patient undergoes 1 PRP injection to the left hip using an anterior approach. 8cc PRP is placed with ultrasound guidance as noted.

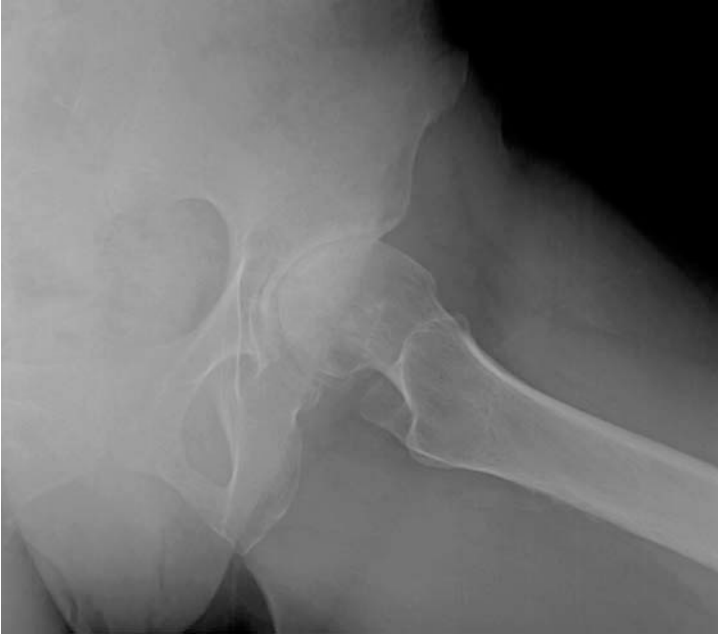

Fig. 9 X-ray left hip following PRP matrix graft series. X-ray shows subtle smoothing of the irregular femoral head surface

After 3 months the patient reports 75% pain improvement and some improvement in ROM is also reported. The night pain has resolved and the patient's pain is controlled with acetaminophen. She is able to resume dance and activities for fitness and health.

Bone and periosteal use of PRP: A review and case example

Gandhi et al. observed normalized cellular proliferation and chondrogenesis with an improved mechanical strength when PRP was injected percutaneously in a diabetic experimental femur fracture model (35).

Sanchez et al. utilized PRP after reattachment of a large (2 cm) loose chondral body in its crater in the medial femoral condyle. Autologous plasma (PRP) was injected into the area between the crater and the fixed fragment. They state that complete articular cartilage healing was considerably accelerated, and the functional outcome was excellent, allowing a rapid resumption of symptom-free athletic activity (36).

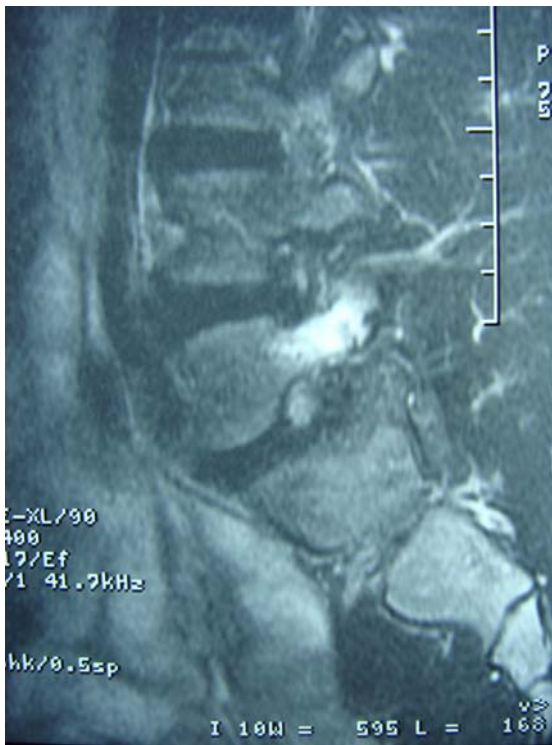PRP has been used successfully in maxillofacial surgery in several studies including a randomized trial of 88 patients with mandibular defects treated

with cancellous cellular marrow grafts with or without PRP. Grafts with PRP showed twice the radiographic maturity at 6 months follow up (2).

Another case report describes a fifty-year old woman with nonunion of humerus who had undergone two unsuccessful operations. Union was obtained by the use of autologous platelet-rich gel (PRG). At the 8th week over 75% of the circumference of the bone at the defect site had resolved and during later visits remodeling of the union was observed on X-ray films and DEXA examinations. Maximum healing was reached at the 18th week. 12 months after PRG injection the intramedullary nail that had previously been placed was removed (37).

Case Example: Bilateral pars interarticularis stress fractures (spondylolysis)

14yo softball player with a history of developing back pain over a period of 6 weeks made worse 4 weeks prior after a minor motor vehicle crash. The patient had initial pain and localized tenderness on the right low back L4-5 area with a positive stork test. X-ray and MRI confirm spondylolysis of the L5 vertebral pedicle.



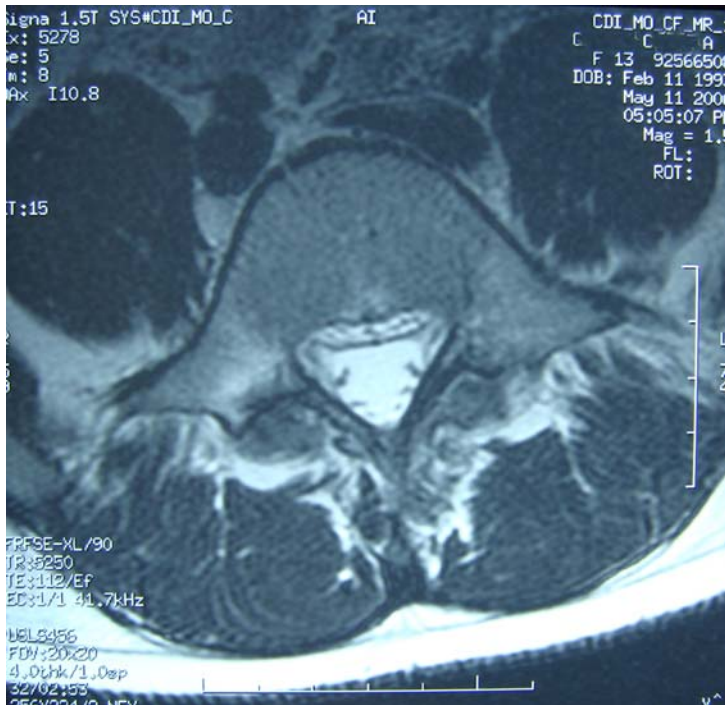

Fig. 10 MRI (initial) of the LS spine shows right sided pedicle stress reaction at vertebral level L5

The patient undergoes extensive physical therapy for approximately 8 months with subsequent partial relief. The patient then returns to sport specific activity but pain redevelops. After appropriate discussion of the benefits and risks, a PRP matrix graft is placed on the right L5-S1 facet joint and the L5 pars with ultrasound guidance. On return to activity the patient notes NO pain on the right pars or low back area. The patient is allowed to slowly return to activity. Two months following the initial PRP graft the patient develops pain in the opposite, left lumbar area after repeated throwing drills. A repeat MRI shows a left sided spondylosis at the L5 vertebrae. No listhesis is appreciated. Evidence of healing is noted on the right pars stress fracture to a small degree.

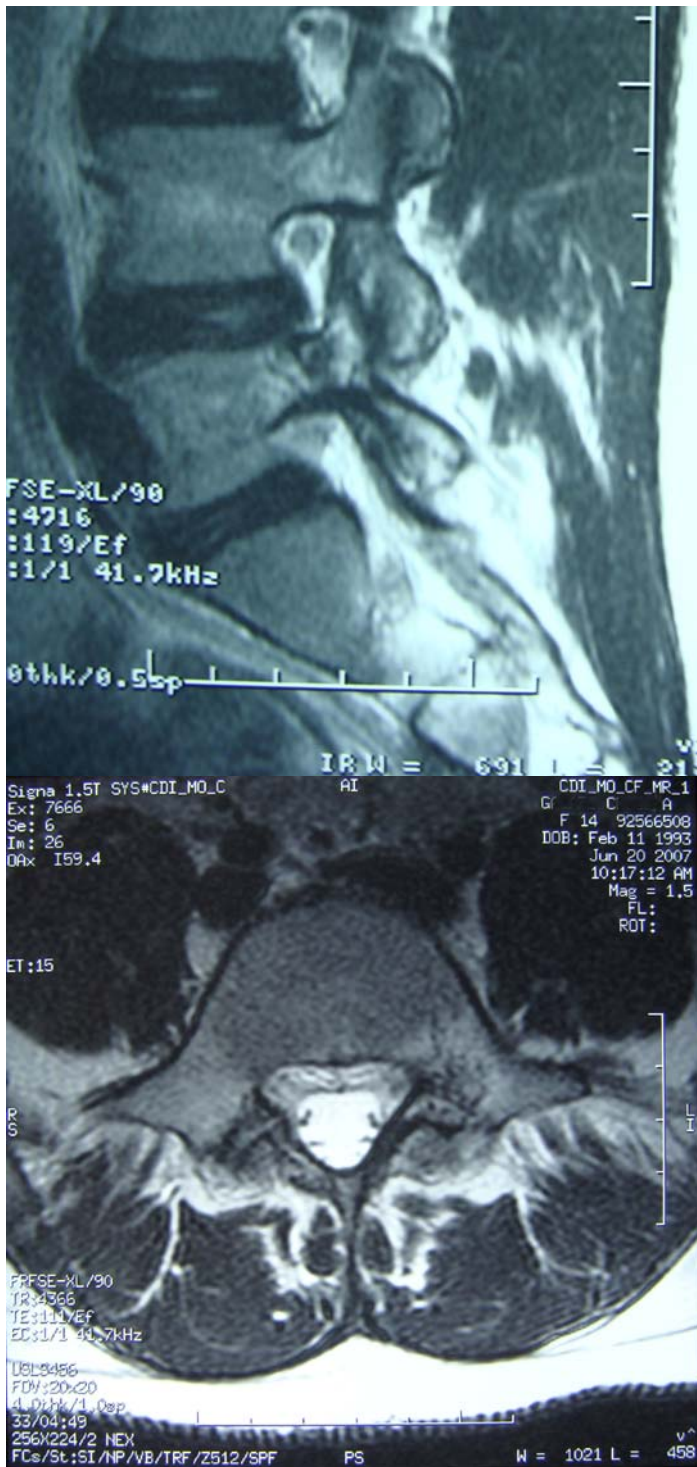
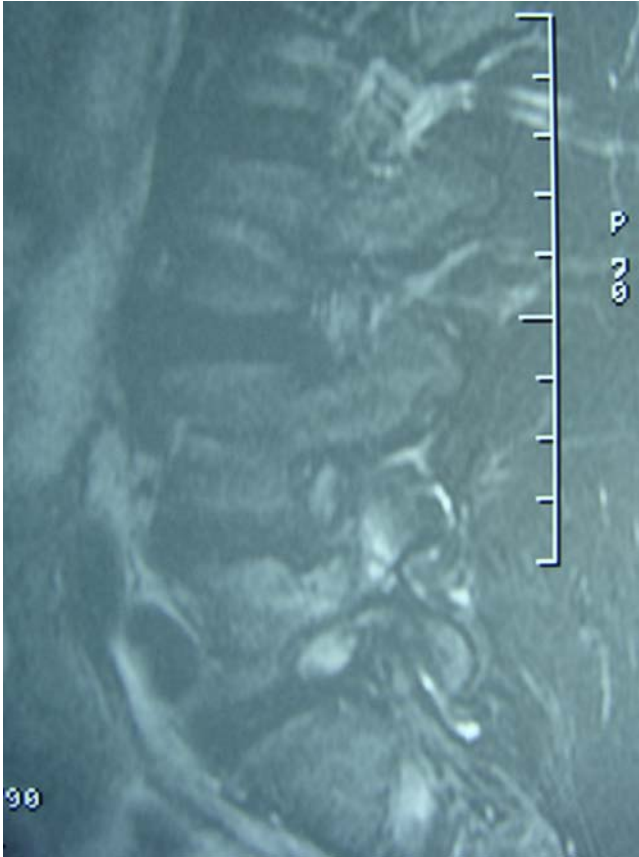


Fig. 11 MRI repeat LS spine (approx. 1 year following the initial MRI) with evidence of new left pars defect at L5 with evident partial healing of right sided stress fracture

PRP matrix grafts with total 8cc PRP at a concentration of 6 fold mixed with 2 cc 50:50 lidocaine 1% with marcaine 0.5%. This PRP matrix graft was

then placed an additional X3 on the right and X3 on the left with approximately 5cc placed at the levels of the L5 pars as well as the accompanying facet joints. The patient was started on physical therapy at two weeks into the graft injection series with progression at 6 weeks to pilates therapy and then sport specific activity. Heavy focus is paid on the mechanics of core stabilization and kinetic chain reintegration. Repeat MRI is obtained two months following PRP.



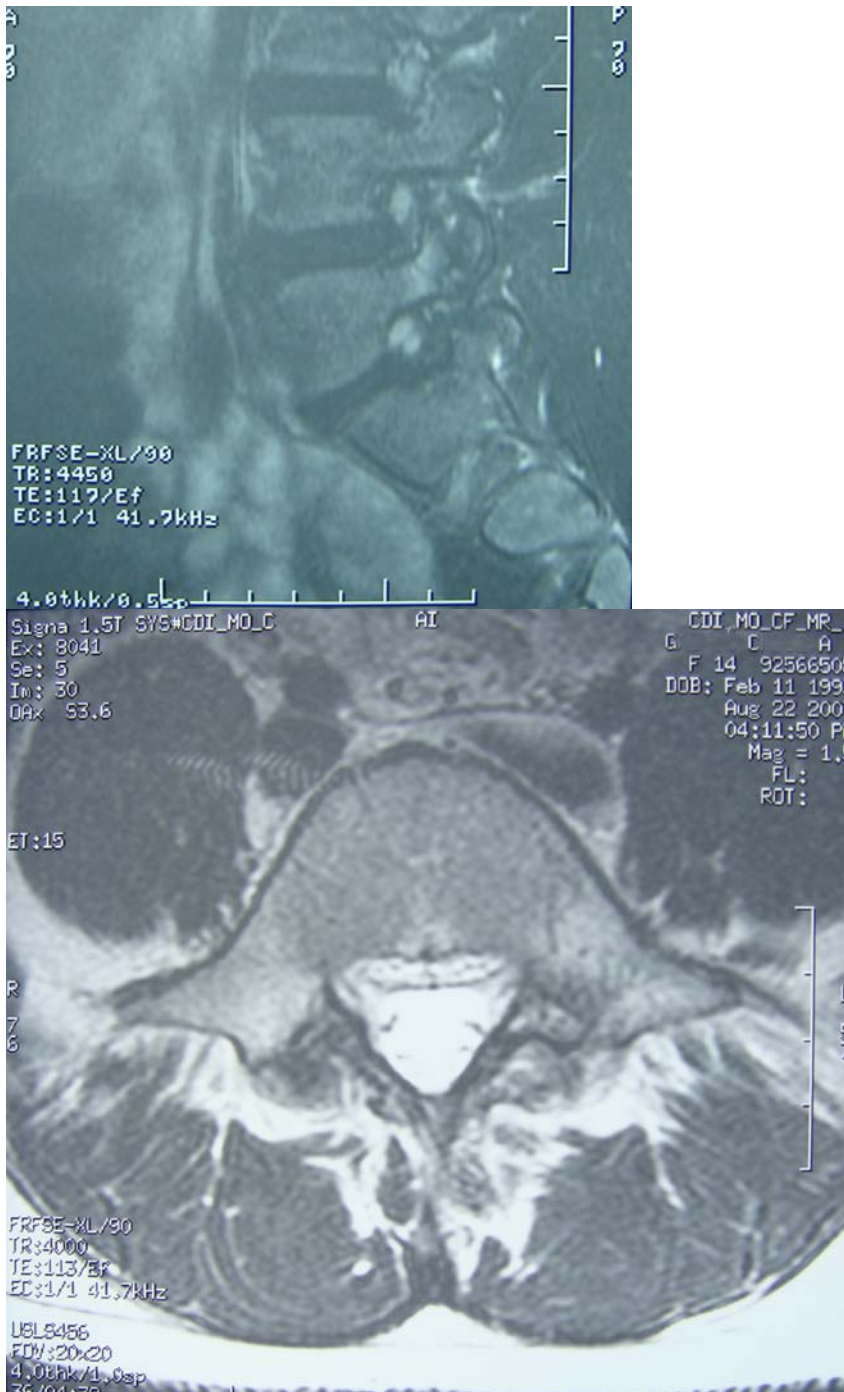


Fig. 12 MRI repeat following four right sided and three left sided PRP matrix grafts with evident interval healing

This shows interval healing of the fracture sites. The patient has not developed any re-occurrence of pain and is back to softball activities with no bracing. No tenderness remains at the prior fracture sites on physical exam.

Skin, range of motion, and pain with the use of PRP: In-Vivo Studies

A prospective, single-blind pilot study comprising 80 full-thickness skin punch wounds (4 mm diameter) was conducted on the thighs of 8 healthy volunteers. With each subject serving as his or her own control (5 punch sites per leg), PRP was applied topically on one thigh, and an antibiotic ointment and/or a semi-occlusive dressing was applied on the other thigh. On day 17, the percentage of closure was 81.1% for the PRP-treated sites and 57.2% for the control sites. Also, the PRP wound closure velocities were significantly faster than those of the controls ($P = .001$). When the platelet count in the gel was more than 6 times the baseline intravascular platelet count in some subjects, epithelialization and granulation formation appeared 3 days earlier in the PRP-treated group (38).

Everts et al. noted improved wound healing when Platelet leukocyte gel (PLG) was applied during wound closure after total knee arthroplasty (5).

In a study examining PRP gel for diabetic foot ulcers, Driver et al. noted that 13 of 19 pts in the study group (68.4%) had complete healing while 9 of 21 (42.1%) of the control group (saline gel). This study was a prospective, randomized, controlled trial with both groups receiving a blood draw for blinding purposes. The treating providers and patients were blinded to the gel applied. It should be noted that no treatment serious adverse events were reported and bovine thrombin used for PRP gel did not cause any Factor V inhibition (39).

In another study from Everts et al. PLG was injected in the subacromial space during wound closure in patients who underwent an open subacromial decompression (40). In the PLG-treated patients, a decrease in the VAS pain score was observed ($p < 0,001$) compared to the non-treated patients. Consequently, the use of pain medication was significant less ($p < 0.001$) in PLG treated patients. Furthermore, treated patients demonstrated a significantly improved range of motion earlier after surgery with a high shoulder functional index.

A significant reduction in pain was also observed by Fanning et al. after PRP applications in gynecologic surgery (41), Gardner and co-workers following total knee replacement surgery (42) and Crovetti and associates after PRP use in patients with chronic wounds (43).

Conclusion

PRP matrix grafts along with other biologic grafting techniques are becoming more prevalent in the treatment paradigms of musculoskeletal medicine. These PRP matrix grafts provide effective, safe, relatively low-cost treatment options to patients who have the time and wherewithal to allow collagen synthesis and maturation at the graft site. PRP matrix grafts appear to restore tissue homeostasis and biotensegrity of collagen. Other pain inhibiting effects are also present in PRP matrix grafts which allow earlier resumption of pain free activity. It is the author's experiences that these grafts, along with other regenerative grafting options, are *at times* the only viable treatment option for a select group of patients with degenerative myofascial tissue injuries. The authors recommend appropriate first line therapies such as relative rest, appropriate bracing and kinesiotaping, evaluation of kinetic chain mechanics, and physical therapy with or without eccentric loading protocols prior to the utilization of these PRP matrix grafting protocols.

Reduction in pain after PRP applications has been observed by several authors. However, an explanation of this phenomena has not always been given. The authors believe that serotonin released from activated platelets might be responsible for decreased pain, as described by Everts (40) and Fanning (41). Except for the growth factors in the Alpha-granules, large amounts of serotonin (44) are contained within the dense platelet granules. Since platelet counts of the PRP are generally almost six fold higher, when compared to whole blood levels, serotonin levels are therefore also significantly increased at the wound site. This phenomena has been explained in detail by Spratt et al. (45) who reported on pain reduction following acupuncture and measured a decrease in serotonin concentration in platelets from these patients and an increase in serotonin levels in plasma, suggesting normalization of plasma serotonin levels due to the mobilization of platelet serotonin.

Other grafting tools such as the use of autologous bone marrow aspirate stem cells (BMAC) with PRP matrices have not been explored in this article but may be found in further detail by the authors. These stem cell / growth factor grafts are being utilized for severe degenerative states with associated tissue hypoxemia. Hence, PRP and other regenerative biocellur therapeutic matrices deserve further study to determine their effects in animal and human models.

About the Authors:

David M. Crane MD practices Sports Medicine in Chesterfield and Saint Louis, Missouri. He is Board Certified in Emergency Medicine and Sports Medicine. Dr. Crane is the founder and Director of the Crane Clinic Sports Medicine. Dr. Crane utilizes the most up to date therapies to assist the healing process in his patients, including Regenerative Injection Therapy (RIT) which uses the patient's own growth factors, or bioactive proteins, to encourage the in-growth of normal collagen and remodeling of injured tissue. He may be contacted at: Crane Clinic Sports Medicine, 219 Chesterfield Towne Centre, Chesterfield, MO 63005, or by email through his website at www.craneclinik.com.

Peter A.M. Everts, PhD heads the Department of Peri-Operative Blood Management at Catharina Hospital at Eindhoven, The Netherlands. Dr. Everts has done pioneering work involving autologous platelet rich plasma in both animal and human trials and wrote the 2007 thesis titled: Autologous Platelet-Leukocyte-Enriched Gel: Basics and Efficacy, which describes a novel method to support soft tissue and bone healing (ISBN ISBN 10: 90-8590-016-6, ISBN 13: 978-90-8590-016-0). Dr. Everts may be contacted via email at everts@elive.nl

Bibliography

1. Ferrari M, Zia S, Valbonesi M, et al. A new technique for hemodilution, preparation of autologous platelet-rich plasma and intraoperative blood salvage in cardiac surgery. *Int J Artif Org.* 1987;10: 47–50.
2. Gamradt, Seth C. et al. Platelet Rich Plasma in Rotator Cuff Repair. *Techniques in Orthopaedics* 22(1):26–33
3. Everts, Peter A.M. et al. Platelet-Rich Plasma and Platelet Gel: A Review *JECT.* 2006;38:174–187
4. Rivera, John and Stephenson, Frank. Personal communication with author 03/06.
5. Everts, P.A. et al. Reviewing the Structural Features of Autologous Platelet-Leukocyte Gel and Suggestions for Use in Surgery. *Eur Surg Res* 2007;39:199–207
6. Ibelgaufts, Horst. C O P E Cytokines & Cells Online Pathfinder Encyclopaedia Version 19.4 (April 2007). <http://www.copewithcytokines.de/>. Last visited 12.09.07

7. Kevy SV, Jacobson MS: Comparison of methods for point of care preparation of autologous platelet gel. *J Extra Corpor Technol* 2004; 36: 28–35.
8. Marx RE. Platelet-rich plasma (PRP): what is PRP and what is not PRP? *Implant Dent* 2001;10:225–228.
9. Kumar: Robbins and Cotran: Pathologic Basis of Disease, 7th ed. Chapter 2 - Acute and chronic inflammation. Copyright 2005 Saunders. Available on www.mdconsult.com.
10. Hesham El-Sharkawy et al. Platelet-Rich Plasma: Growth Factors and Pro- and Anti-Inflammatory Properties. *J Periodontol*. April 2007 ;78:661-669.
11. Haynesworth, Stephen et al. Mitogenic Stimulation of Human Mesenchymal Stem Cells by Platelet Releasate. Poster Presentation, American Academy of Orthopedic Surgery, March 2001.
12. The Healing Effects of Autologous Platelet Gel on Acute Human Skin Wounds. *Arch Facial Plast Surg*. 2007 May-Jun;9(3):174-83
13. Weibrich G, Hansen T, Kleis W, Buch R, Hitzler WE. Effect of platelet concentration in platelet-rich plasma on peri-implant bone regeneration. *Bone*. 2004;34:665–71.
14. Liu, Yawei BA et al. Fibroblast Proliferatiion due to Exposure to a Platelet Concentrate in Vitro is pH Dependent. *Wound Rep Reg* 2002; 10:336-340.
15. Jorge de la Torre, MD, FACS.
http://www.emedicine.com/plastic/topic477.htm#section~the_physiology_of_healing_of_the_chronic_wound. Last Updated: May 26, 2006. Last visited 12/09/07.
16. Michael D. Barnett Jr, MD and Gregory C. Pomeroy, MD. Use of Platelet-Rich Plasma and Bone Marrow Derived Mesenchymal Stem Cells in Foot and Ankle Surgery. *Techniques in Foot and Ankle Surgery* 6(2):89–94, 2007

17. www.Harvesttech.com. Last visited 12/09/07.
18. Olena Virchenko and Per Aspenberg. How can one platelet injection after tendon injury lead to a stronger tendon after 4 weeks? Interplay between early regeneration and mechanical stimulation. *Acta Orthopaedica* 2006; 77 (5): 806–812
19. Ingber, Donald E. The Architecture of Life A universal set of building rules seems to guide the design of organic structures—from simple carbon compounds to complex cells and tissues. *Scientific American* January 1998:48-57.
20. Ingber, Donald E. Cellular tensegrity: defining new rules of biological design that govern the cytoskeleton. *Journal of Cell Science* 104, 613-627 (1993)
21. Creaney, Leon and Hamilton, Bruce. Growth Factor Delivery Methods in the Management of Sports Injuries: The State of Play. *Br. J. Sports Med.* Published online 5 Nov 2007;10.1136/bjism.2007.1-16
22. T. M. Bielecki et al. Antibacterial effect of autologous platelet gel enriched with growth factors and other active substances; an in vitro study. *The Journal of Bone and Joint Surgery*. VOL. 89-B, No. 3, MARCH 2007. 417-420
23. Scott JD, Pawson T. Cell communication: The inside story. *Sci Am.* 2000;282:72
24. Anitua, Eduardo et al. Autologous preparations rich in growth factors promote proliferation and induce VEGF and HGF production by human tendon cells in culture. *Journal of Orthopaedic Research* 23 (2005); 281–286
25. Mishra, A, et al, Human Skin Fibroblast Proliferation in Buffered Platelet Rich Plasma, American Academy of Orthopaedic Surgeons Poster Presentation, March, 2006
26. Schnabel, L, et al, Platelet Rich Plasma (PRP) Enhances Anabolic Gene Expression Patterns in Flexor Digitorum Superficialis Tendons, *Journal of Orthopaedic Research*, 2006; 230-240

27. du Toit, Don F. et al. Soft and Hard-tissue Augmentation with Platelet-rich Plasma: Tissue Culture Dynamics, Regeneration and Molecular Biology Perspective. *Int J Shoulder Surg.* April 2007; vol 1:2; 64-73
28. Mishra, A, et al, Treatment of Chronic Elbow Tendinosis with Buffered Platelet-Rich Plasma, *American Journal of Sports Medicine*, 2006, 34:1774-1778
29. Barett, S, Growth Factors for Chronic Plantar Fasciitis?, *Podiatry Today*, 2004, 17:36-42
30. Scarpone, M, et al, PRP as a Treatment Alternative for Symptomatic Rotator Cuff Tendinopathy for Patients Failing Conservative Treatment, 2005
31. Ventura, A, et al, Use of Growth Factors in ACL Surgery: Preliminary Study, *Journal of Orthopaedic Traumatology*, 2005, 6:76-79
32. Sanchez M, Anitua E, Azofra J et al. Comparison of surgically repaired Achilles tendon tears using platelet-rich fibrin matrices. *Am J Sp Med* 2007;35(2):245-251
33. Sanchez, M, et al, Application of Autologous Growth Factors on Skeletal Muscle Healing, *2nd World Congress on Regenerative Medicine Podium Presentation*, May, 2005
34. Everts, Peter A. M. and Devilee, Roger et al. Autologous platelet gel and fibrin sealant enhance the efficacy of total knee arthroplasty: improved range of motion, decreased length of stay and a reduced incidence of arthrofibrosis. *Knee Surg Sports Traumatol Arthrosc.* January 2007.
35. Gandhi A, Dumas C, O'Conner JP, Parsons JR, Lin SS. The effects of local platelet delivery on diabetic fracture healing. *Bone.* 2006; 38:540-6
36. Sanchez, M, et al, Plasma Rich in Growth Factors to Treat Articular Cartilage Avulsion: A Case Report, *Medicine & Science in Sports & Exercise*, 2003, 1648-1652

37. Tomasz Mariusz Bielecki: Percutaneous Injection Of Autogenous Growth Factors In Patient With Nonunion Of The Humerus. A Case Report. *J.Orthopaedics* 2006;3(3)e15
38. The Healing Effects of Autologous Platelet Gel on Acute Human Skin Wounds. *Arch Facial Plast Surg*. 2007 May-Jun;9(3):174-83
39. Driver, Vickie et al. A Prospective, Randomized, Controlled Trial of Autologous Platelet-Rich Plasma Gel for the Treatment of Diabetic Foot Ulcers. *Ostomy / Wound Management* 2006; 52(6): 68 – 87
40. Everts PAM, Devilee RJJ, Brown Mahoney Chr, et al. Exogenous application of platelet-leukocyte gel during open subacromial decompression contributes to improved patient outcome. A prospective randomized double-blinded study. *Eur Surg Res* 2008;40:203–210
41. Fanning J, Murrain L, Flora R, Hutchings, Johnson J, Fenton B. Phase I/II prospective trial of autologous platelet tissue graft in gynaecologic surgery. *J Min Invas Gyn*. 2007; 14: 633-637.
42. Gardner MJ, Demetrakopoulos D, Klepchick PR, Mooar PA (2006) The efficacy of autologous platelet gel in pain control and blood loss in total knee arthroplasty. *Int Orthop* 2006; 31: 309-313.
43. Crovetti G, Martinelli G, Issi M, et al. A. Platelet gel for healing cutaneous chronic wounds. *Transfusion and Apheresis Science* 30. 2004; 145-151
44. Vanhoutte PM: Platelet-derived serotonin, the endothelium, and cardiovascular disease. *J Cardiovasc Pharmacol* 1991; 17S:S6–S12.
45. Sprott H, Franke S, Kluge H, Hein G: Pain treatment of fibromyalgia by acupuncture. *Rheumatol Int* 1998; 18: 35–36.